



PATIENT SPOTLIGHT

Not Bell's Palsy

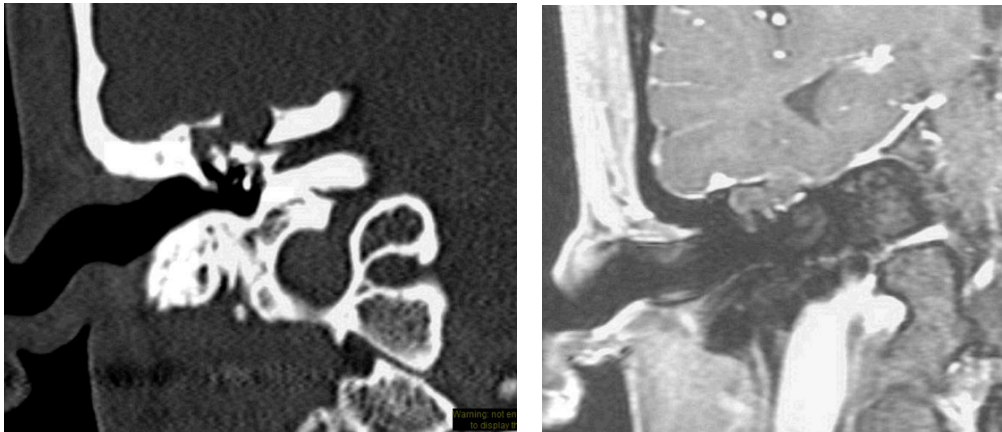


Fig 1 - a) Coronal CT, showing soft tissue mass in epitympanum, with tegmen erosion. b) MRI, T1-weighted Gd + coronal image, showing non-enhancing epitympanic lesion, with secondary soft tissue opacification of mastoid cells

A 24 year old male patient presented with right facial palsy of 5 months duration. He had mild hearing loss in the right ear but denied any other symptoms.

CLINICAL SIGNS

The patient was treated by a neurologist for “Bell’s palsy” with high-dose prednisone but there was no improvement in facial nerve function. Exam showed an intact eardrum with soft tissue convexity in the attic, and a complete (grade 6/6) facial paralysis. CT revealed an erosive mass in the epitympanum (Fig. 1a), and MRI showed imaging characteristics consistent with epidermoid tumor (Fig. 1b). ENoG showed no response at maximal stimulation levels. EMG showed marked spontaneous activity in the facial muscles.

CLINICAL FINDINGS

At surgery, there was a keratin mass in the epitympanum (Fig. 2), with bony erosion of the tegmen and the tympanic segment of the fallopian canal, and a fistula of the lateral semicircular canal. The mass was removed via canal wall down mastoidectomy. The tegmen was repaired with cartilage. The facial nerve was explored and the bony fallopian canal was found to be dehiscant from the labyrinthine segment to the second genu (Fig.3). The nerve was anatomically intact, but compressed by the lesion. The nerve was surgically decompressed, removing the matrix from the exposed facial nerve sheath. Stimulation of the nerve proximal to the lesion produced a weak response at a threshold level of 0.8 mA. Post-operatively the patient did well. At 2 months, the facial nerve function recovered partially to a grade 4/6 level.



ENT and Allergy
Associates, LLP

This patient was
referred by a tri-state
ENTA physician.

Our shared EHR
facilitates a seamless
referral process and
transfer of medical
records with the push of
a button.

To refer a patient:

Call us direct at
Physician Access Services
(212) 241-4983

Thank you for your
referrals.

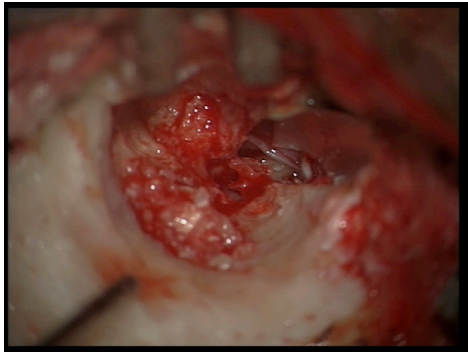


Fig 2 - Epidermoid tumor filling epitympanum

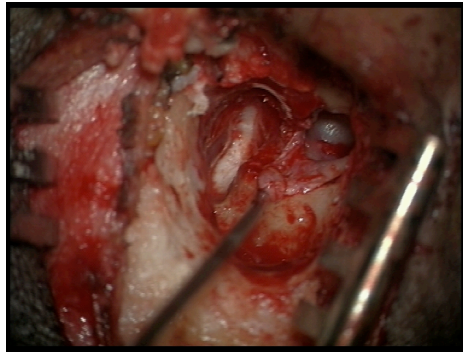


Fig 3 - Instrument touching dehiscence facial

MOUNT SINAI OTOLARYNGOLGY

Eric M. Genden, MD
Chairman
Head and Neck Cancer

William Lawson, MD, DDS
Vice-Chairman
Rhinology and Facial Plastics

Satish Govindaraj, MD
Director, Endoscopic Skull
Base Surgery

Alfred Illoreta, MD
Rhinology and Skull
Base Surgery

Fred Y. Lin, MD
Director, Sleep Surgery

Brett A. Miles, MD, DDS
Head and Neck Cancer

Joshua D. Rosenberg, MD
Facial Plastics,
Head and Neck Cancer

Eric E. Smouha, MD
Director, Otolaryngology and
Neuro-Otology

Marita S. Teng, MD
Head and Neck Cancer

Mike Yao, MD
Head and Neck Cancer

Manhattan:

Faculty Practice Associates
5 East 98th Street, 8th Floor
New York, NY 10029

Center for Science and Medicine
10 East 102nd St, 3rd Floor
New York, NY 10029

Staten Island:

2052 Richmond Road, Suite C
Staten Island, NY 10306

Long Island:


325 Park Avenue
Huntington, NY 11743

DISCUSSION

Certain clinical features that are not characteristic of Bell's palsy deserve mention, because these should trigger a search for another etiology (see below). Palsy that is gradual in onset (greater than 72 hours) should raise the suspicion of a lesion causing extrinsic compression of the nerve, such as a cholesteatoma or neoplasm of the facial nerve, skull base, or parotid. Palsy that spares the brow and mimetic function is central in origin, and should raise the possibility of stroke; likewise facial paresis accompanied by somatic hemiparesis should suggest pathology in the motor cortex of the brain. Polycranial neuropathies could be associated with central nervous system pathology or skull base tumors (see above). Segmental facial palsy (i.e., sparing of certain branches) should raise the suspicion of a lesion distal to the stylomastoid foramen, such as a parotid tumor. Facial paralysis that fails to show any sign of recovery after 4 months is also suspicious, as all cases of Bell's palsy will show at least partial return of function within that time frame. Patients who have a history of a previous malignancy should be worked up for the possibility of metastatic disease. Although Bell's palsy is the most common cause of facial paralysis, this is a diagnosis of exclusion. The differential diagnosis is broad. Making a correct diagnosis is essential for proper treatment, and function can be regained in many cases.

Clinical Features not typical of Bell's Palsy

- Gradual Onset
- Hyperkinesia
- Bilateral simultaneous palsy
- Associated neurological symptoms
- History of malignancy
- Slow progression beyond 2 weeks
- Segmental paralysis/paresis
- Presence of other cranial neuropathies
- Absence of recovery by 4 mos



By Eric Smouha, MD

Associate Professor
Department of Otolaryngology

Dr. Smouha is the Director of Otolaryngology and Neuro-otology at Mount Sinai. His clinical interests include hearing restoration, chronic ear disease, and lateral skull base tumors.